

Volume 2 Issue 2

2025

DOI: 10.5281/
zenodo.15192257

Corresponding Author

Dr. Adityendu Chakraborty
Department of Dermatology,
Nil Ratan Sircar Medical
College,
Kolkata—14
E-mail: adityenduchakrabort-
yac@gmail.com

Available from: [https://
esrfjums.co.in/index.php/main/
article/view/49](https://esrfjums.co.in/index.php/main/article/view/49)

Published by: Eureka Scientech Research
Foundation, Kolkata.

Online access: <https://esrfjums.co.in>

Images in Dermatology

Adityendu Chakraborty¹, Arun Achar²

¹Post Graduate Trainee, Dermatology, Nil Ratan Sircar Medical College, Kolkata

²Professor and Head, Dermatology, Nil Ratan Sircar Medical College, Kolkata

CASE 1

20 years old farmer noticed reddish, annular, itchy and mild scaly lesions over his trunk, neck, groin, face, limbs around 6 months back. Initially lesions were small, but gradually they increased in size and itching sensation got increased. On the advice of a quack, patient applied Dithranol, causing burning, stinging sensations along with more erythema on those sites. At the Dermatology OPD he was then diagnosed as a case of Tinea Corporis + Tinea Cruris + Tinea Faciei with Secondary Irritant Contact Dermatitis Due to Derobin Cream Application. The patient was started on Prednisolone, Topical Emollients And Topical Mupirocin For few weeks. Following this, treatment for tinea was started with oral Itraconazole, Cetirizine and topical miconazole. After 2 months of treatment patients's lesions became faint, so he thought his treatment is completed and didn't turn up for follow up. Similar lesions developed over the body again. He was now diagnosed a case lost to follow up/treatment absconder of Tinea Corporis + Tinea Cruris + Tinea Faciei.

The patient did not have a history of systemic disease or regular medications. The patient is currently on oral Itraconazole, Cetirizine and topical miconazole. He has been asked to report for follow up after 2 weeks.

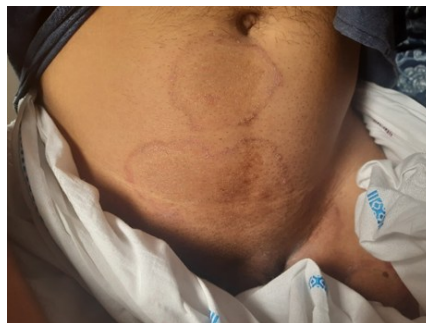

Image 1: Presenting lesions of the patient

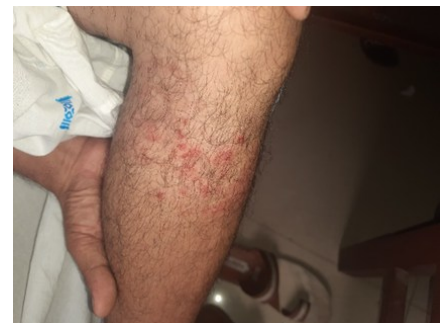

Image 3: Lesions following abrupt stoppage of treatment

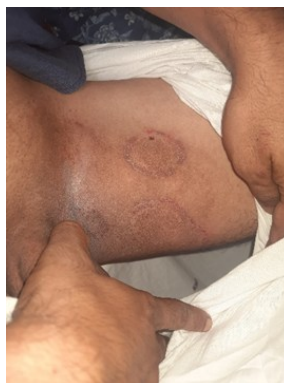

Image 2: Lesions that appeared following abrupt stoppage of treatment

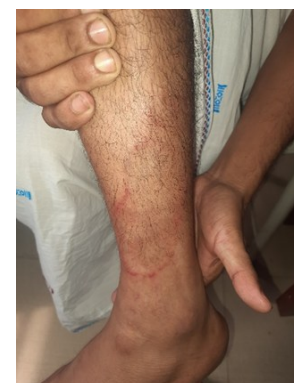

Image 4: Current status of the lesions.

CASE 2

60 years old female visited Dermatology OPD with ulcerative and indurated nodular lesions over her left forearm. The lesions are painless, gradually increasing in size and number for past 3 years. 3 years back she had a history of prick injury over left forearm by a twig in garden prior to development of such lesions. Positive Fungal culture from tissue biopsy sample, HPE and clinical presentation confirmed the diagnosis of Cutaneous Sporotrichosis.

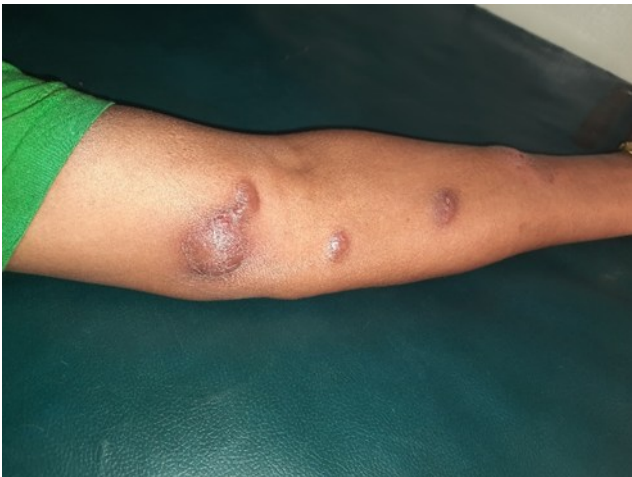

Image 1: Presenting lesions of the patient

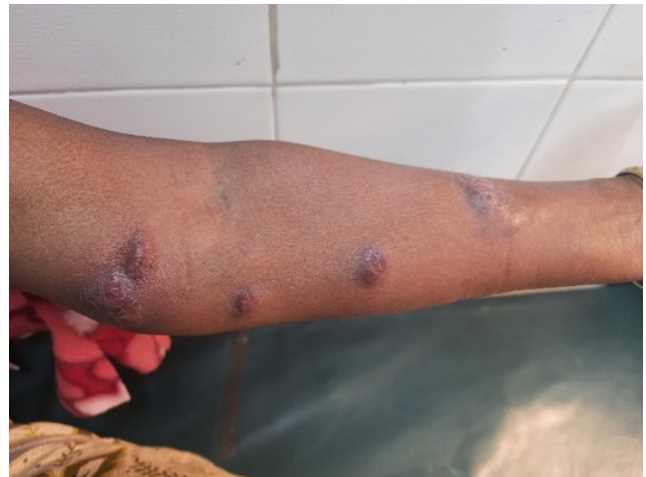

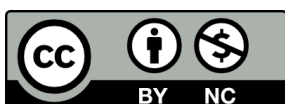
Image 2: Ulcerative inundating nodules

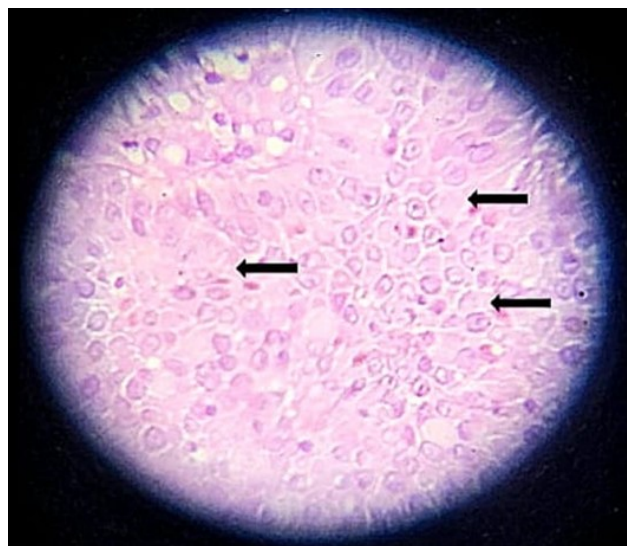

Image 3: HPE showing *Sporothrix schenckii*.

Declaration of patient consent:

Appropriate patient consent was obtained by the authors for taking and sharing pictures.



Articles in The ESRF Research Journal for Undergraduate Medical Students are Open Access articles published under a Creative Commons Attribution-Non Commercial 4.0 International License (CC BY-NC). This license permits use, distribution, and reproduction in any medium, provided the original work is properly cited, but it cannot be used for commercial purposes and it cannot be changed in any way.